

PATIENT

Chica Sack

SPECIES

Canine

BREED

Chihuahua

SEX

FS

AGE

14 years

WEIGHT

11.9 lbs

INTERPRETED BY

Maggie Machen Lamy,
DVM, DACVIM
(Cardiology)

IMAGING PERFORMED BY

HOSPITAL NAME

SVSCT

REFERRING VET

Dr. Babich

INVOICE

47282

DATE

3/26/26

PRESENTING CLINICAL SIGNS

History: Follow up after echo.
11-25 echo (BS/SVS): CVD B1, MR/TR. Mild PAH
Medications: Pimobendan, Sildenafil, Meloxicam
DIARY: Included

HOLTER MONITOR FINDINGS AND RHYTHM ASSESSMENT

Time analyzed	23:42h
Mean heart rate	80bpm
Maximum heart rate	234bpm
Minimum heart rate	40bpm
VPCs	1
APCs	43 singles

Interpretation: Underlying normal sinus rhythm with appropriate rate. The max heart rate is sinus in origin and correlates with activity. Isolated APCs are seen throughout; mostly singles with occasional couplets. A single VPC as well as rare escape beats are seen. Occasional brief sinus pauses while sleeping. Max heart rate is sinus in origin and during waking hours (no correlation to the diary is seen).

Rhythm diagnosis: Sinus rhythm with respiratory variation. Isolated APCs and rare VPCs.

INTERPRETATION OF THE FINDINGS & FURTHER RECOMMENDATIONS

The underlying rhythm appears normal, without significant pauses or AV block. Atrial premature contractions (APCs) are identified throughout; however, only single beats are observed and are relatively infrequent. A single VPC in 24 hours is of little concern.

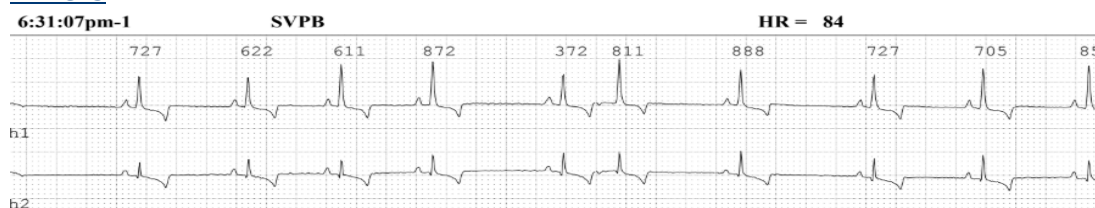
No treatment for the APCs is indicated at this time as there is low risk for complication. Omega fatty acid supplementation is recommended in any arrhythmic patient.

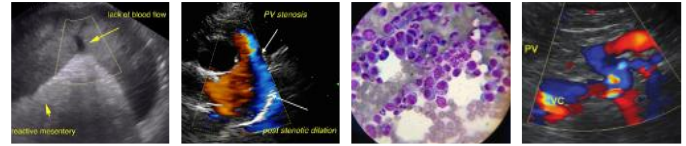
Monitor for signs of sustained arrhythmias, such as acute lethargy or collapse.

Plan: Recheck echocardiogram recommended as dictated by the echo report.

A recheck ECG and/or holter is recommended if clinical signs of sustained arrhythmias is noted, or in 1 year.

IMAGES





PATIENT

Chica Sack

SPECIES

Canine

BREED

Chihuahua

SEX

FS

AGE

14 years

WEIGHT

11.9 lbs

INTERPRETED BY

Maggie Machen Lamy,
DVM, DACVIM
(Cardiology)

IMAGING PERFORMED BY

HOSPITAL NAME

SVSCT

REFERRING VET

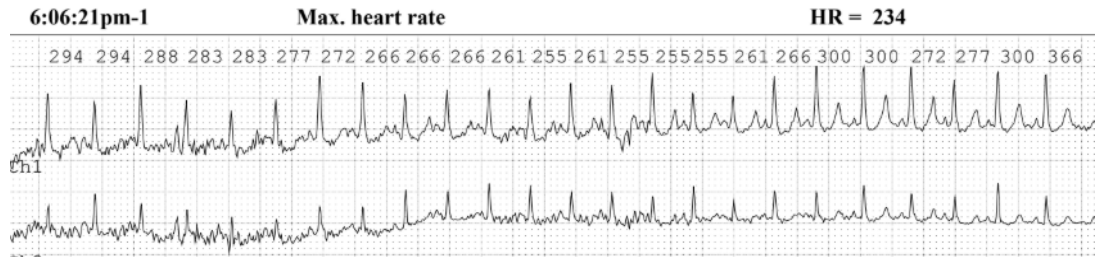
Dr. Babich

INVOICE

47282

DATE

3/26/26



The information and recommendations provided are based on the images presented by the referring veterinarian. No evaluation can be communicated regarding pathology that was not visible in the image/video clips provided.

Thank you for this referral. If the clinical or image interpretation does not parallel your findings or if I can be of any further assistance please contact me.

Maggie Machen Lamy, DVM
Diplomate of the American College of Veterinary Internal Medicine (Cardiology)
 info@sonopath.com